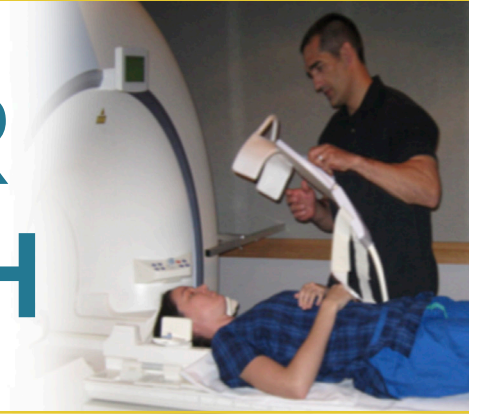

WAGING WAR ON WHIPLASH



Researchers at Northwestern University Feinberg School of Medicine study MRI scans for the miniscule differences between full recovery and long-term chronic pain following whiplash injuries from a motor vehicle collision (MVC). Analyze captures valuable quantitative MRI data that informs better research.

“We’re making breakthroughs in our quantitative MRI findings and Analyze is powering such breakthroughs. The analyses of our research data are faster and easier using Analyze, which allows us to get to clinical findings – and possible solutions – more quickly.”



JIM ELLIOTT, PHD
Northwestern University
Feinberg School of Medicine



Jim Elliott, PhD, PT, remembers thinking to himself that he must be missing something. As a physical therapist working in the late 1990’s, he would see whiplash patients with chronic pain-related disability following a motor vehicle collision (MVC) on a daily basis, yet he couldn’t find any good data on likely indicators for full recovery versus long-term chronic pain.

Whiplash is one of the most common head and neck injuries, often a result of rear-impact MVC. Elliott was fascinated by the seemingly random recovery rate experienced by whiplash patients. While some patients would recover quickly, others were faced with long-term pain-related disability – lasting months or even years.

“There was often a med-legal case and yet we had very little, if any, objective data or insights that were helpful in assessing the severity or long-term damage of the injury,” said Elliott, Assistant Professor in Physical Therapy and Human Movement Sciences at Northwestern University Feinberg School of Medicine.

“I started talking to radiologists in the area asking their opinions and asking them about what MRI might show,” said Elliott. “There was rarely an obvious lesion or abnormality on the scans so we decided to change our focus and take a closer look at the muscles in the neck, which has opened up new possibilities for explaining persistent pain-related disability following whiplash.”

His professional curiosity led him to the University of Queensland in Brisbane, Australia, where he completed his doctoral studies in 2007

and his post-doctoral fellowship in 2010. It was there he started his intense focus on MRI scans and first learned about Analyze and how it could help with his research on whiplash.

“We needed a more powerful analysis platform to quantify our MRI research and we selected Analyze,” said Elliott. “It can handle any data we load into it, and we find that it is simply easier to use than other available platforms. It’s made a big difference in the precision, accuracy, and interpretation of our research findings.”

Quantitative MRI Measured and Made Clear

Roughly four million people will seek medical care from emergency medicine departments each year across the U.S. for injuries sustained in a MVC. Such injuries cost approximately \$30 billion per year, but there remains a paucity of available information that medical/rehabilitative treatments are effective at lessening the transition from acute to persistent pain-related disability. Clearly, it’s a problem worth investigating – and solving - as the social, economic, and personal burden is quite large.

“Fifty percent of individuals should expect full recovery within the first 2-3 months after the injury,” said Elliott. “Recovery rates are expected to slow considerably for the other 50 percent with persistent symptoms at three months. Twenty-five percent will present with a markedly complex clinical presentation. In fact, if symptoms persist past six-months, they are unlikely to change in the long-term.” Making an accurate diagnosis of long-term

whiplash risk could enable the exploration and development of more informed early treatments and support. MRI is the gold standard for soft tissue imaging and numerous studies have focused on obvious areas like vertebral discs, joints and ligaments, but this approach has not yielded consistent identification of salient lesions that are related to clinical symptoms.

“We needed a more powerful analysis platform to quantify our MRI research and we selected Analyze. It can handle any data we load into it, and we find that it is simply easier to use than other available platforms. It’s made a big difference in the precision, accuracy, and interpretation of our research findings.”

JIM ELLIOTT, PHD

Northwestern University Feinberg School of Medicine



“We’ve taken a different approach and focused on other factors like visible fat quantities in muscle tissue, which could suggest traumatic factors play a role in their degeneration,” said Elliott. “In treating patients with chronic whiplash, we kept seeing unusual fat deposits on their MRI scans.”

The fat deposits in the muscles of the neck area did not appear to be related to body weight. Elliott had also learned that other researchers had found fat deposits to be associated with lower back pain.

To quantify differences and patterns, and lend credence to clinical theories, Elliott and his research colleagues have loaded hundreds of patient images into Analyze. Volume metrics of height, width, and depth can all be measured and modeled within Analyze.

“For complicated areas like the neck, with so much anatomy in a small area, we’ve found

the 3-D rendering in Analyze to be especially helpful,” said Elliott. “Muscles, vertebrae, and the pharynx are easier to navigate and evaluate in 3-D.”

In addition to the correlation between increased fat deposits and long-term injury, Elliott and his team have also found pharynx characteristics that may indicate long-term problems.

“We’ve been able to use MRI of the oropharynx to create volumetric measurements, using Analyze” said Elliott.

Using Quantitative MRI for Better Whiplash Understanding and Outcomes

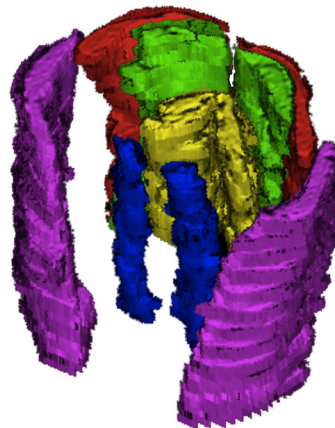
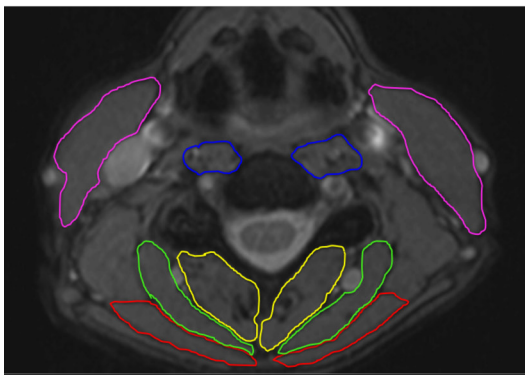
1. Whiplash researchers at Northwestern University use MRI to measure surface area and volume differences in patient physiology.
2. Analyze is their workspace for loading images, and analyzing and capturing measurement data.
3. Variations in muscle fat deposits and pharynx size as measured with Analyze, are new data points for better understanding the acute and chronic whiplash condition.

“It appears that those patients with chronic pain-related disability demonstrate a collapsed oropharynx and this seems to be related to less frequently observed clinical symptoms of voice projection deficits and swallowing difficulty.”

Elliott continues to pursue other anatomical clues from imaging and neurophysiology applications that may solve the mystery of the chronic whiplash condition. And each new finding is one step closer to improved assessments, treatments, and pain reduction for millions of patients around the world..

“We’re making breakthroughs in our quantitative MRI findings and Analyze is powering that,” said Elliott. “Our research is faster and easier using Analyze, which allows us to get to clinical findings – and possible solutions – more quickly.”

Elliott’s work is supported by the National Institutes of Health - NIH 1 R01 HD079076-01A1. Disclosure: Elliott has ownership and investment options in a medical consultation start-up, Pain ID, LLC.



Analyze provides a diverse and powerful array of MRI display tools for data review and display.